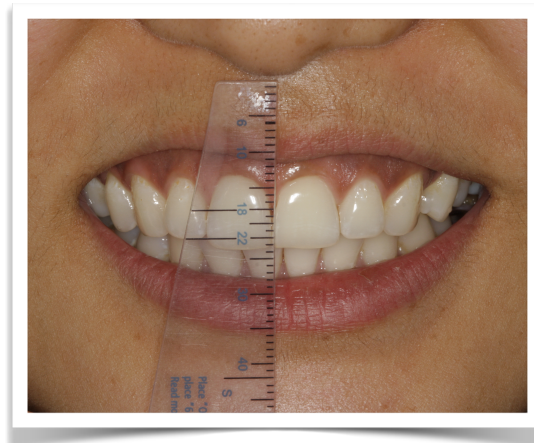
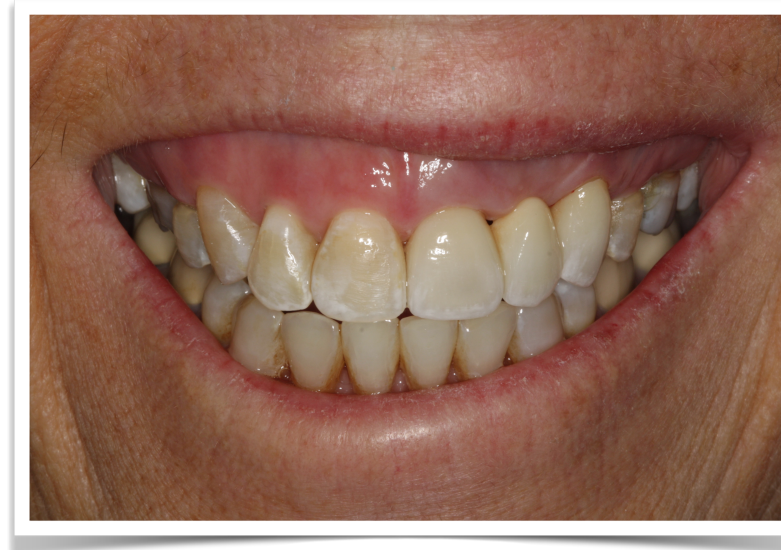
There are **5 measurements** that I take in order to **diagnose** a gummy smile.
This makes the process very **SIMPLE!**

1. **Facial Thirds:** Measure from the glabella to base of nose, and base of nose to inferior border of chin. The middle and lower 1/3 should be equal.
2. **Lip Length and Mobility:** Measure the lip length in repose and at high smile. The difference is the mobility. The average lip LENGTH is 22-24mm. The normal lip MOBILITY is <8mm.
3. **Gingival Line:** Draw a line across the gingival margins of the canines and centrals. The line should be even. If concave, it may indicate dento-alveolar extrusion.
4. **Tooth Size:** The average central incisor length is 9-11mm, and ideally has a 1.2 : 1.0 height to width ratio. When a tooth is short, it could indicate DAE, anatomic variation, or altered passive eruption.
5. **CEJ Detectable:** Altered passive eruption can be diagnosed if the CEJs are undetectable.



Clinical Example



Let's look at this case....

1. Mid face = 62mm, Lower face = 54mm
2. Lip length = 22mm, Lip mobility = 11mm
3. Gingival line = straight
4. Tooth size = normal
5. CEJ = detected

After taking our measurements, we can now make a diagnosis for this patient. Notice her measurements highlighted in red. Her mid-face is longer than her lower-face, which indicates that she may have **vertical maxillary excess (VME)**. In addition, her lip mobility is higher than normal, which indicates a **hypermobile lip**. This example illustrates that patients may have more than one diagnosis contributing to their gummy smile!

*Once the diagnosis is made, each diagnosis then correlates to **Treatment Options**.*

For this patient, the treatment options for her hypermobile lip could include a **lip repositioning surgery and/or botox**. Treatment options for her (VME) could include a surgical **maxillary impaction**. Because she had a normal tooth size with the CEJ detected, **crown lengthening** would not be indicated. And because her gingival line was straight, **orthodontics** may not be indicated to help her gummy smile. In the end, she elected no treatment for her gummy smile. So did you guess correctly?

LOOKING FOR ANOTHER OPINION OR OPTION?
WOULD YOU LIKE TO DISCUSS A COMPLEX CASE OR PROCEDURE WITH A PROSTHODONTIST?
DO YOU HAVE CASES THAT WOULD BE FUN TO BRAINSTORM TOGETHER?
CALL OR E-MAIL US! WE WOULD LOVE TO CHAT.

We are here to assist you in whatever ways which are helpful to you. We want to make your jobs easier. Give us a call, send us an e-mail, or shoot us a text.

*

Virginia Prosthodontics loves a challenge and loves making your life simpler.



About Virginia Prosthodontics

Although the facility is new, Dr. Eskow has been practicing in Northern Virginia for almost 10 years. She now brings her prosthodontic expertise to Loudoun County. Virginia Prosthodontics is a specialty practice focused on the prosthetic needs of patients. A large part of our practice is dependent on our state-of-the-art in-house dental lab, which offers everything from same-day tooth repairs to full-arch porcelain prostheses.

Dr. Eskow is a board-certified prosthodontist and is an expert in cosmetic dentistry, dental implants, dentures, and complete oral rehabilitation. She is an artist and a problem-solver.

We look forward to meeting you and your team. If you are interested in a lunch-n-learn, please reach out! We love meeting other dentists and staff.



VIRGINIA
PROSTHODONTICS

Practice Update:

Construction is underway at Dr. Eskow's new office in Chantilly, VA. The anticipated opening date is February 2023. If you'd like to discuss a case, please reach out and we would love to come meet you!

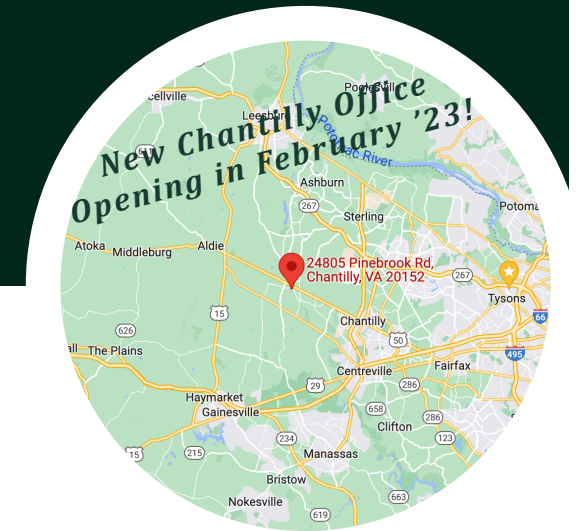
VIRGINIA
PROSTHODONTICS

Newsletter

Caroline Eskow, DDS, MS, FACP

www.DrEskow.com

571-786-5979



INSIDE THIS ISSUE

Case Summary

Gummy Smiles - How to diagnose and what are the treatment options?

Page.....1-3

Behind the Scenes at Virginia Prosthodontics

Our new office!

Page.....4

Who We Are

Do you want to discuss a case?

Page.....4

Diagnosing The Gummy Smile

I'd venture to say that we've all met someone who was looking for a solution for their gummy smile. This person sometimes isn't even aware of their gummy smile, but they know that they don't like their smile for some reason. Well how do we help them?... Turn the page and take a quick peep at the photo on page 3. Now instead of jumping to treatment options (crown lengthening, veneers, lip repositioning, etc...), I encourage you to take a step back and determine the diagnosis first. If you do, the treatment options available will become obvious!

Let's start by going through the diagnosis together...